



## PATIENT

Rodrigo Davila  
Gonzalez

## PRESENTING CLINICAL SIGNS

History: Recheck echo. Grade 3/6 heart murmur.  
-Pertinent previous echo findings (10/2022 MML): Moderate MR, mild LAE. LV: 3.7, LA: 2.0.

## SPECIES

Canine

## BREED

Miniature Schnauzer

## SEX

Male Neutered

## ECHOCARDIOGRAM FINDINGS

2D, m-mode, color flow and doppler imaging is available. Diffuse thickening of mitral valve leaflets with prolapse into the left atrial lumen. Moderate eccentric mitral regurgitation with moderate left atrial dilation. Normal MR velocity. Normal LV diameter with adequate myocardial function. The tricuspid valve appears normal with mild tricuspid regurgitation. Normal velocity. Normal right atrial and ventricular diameter and morphology indicating no overt evidence of pulmonary arterial hypertension. The pulmonic and aortic valves are normal in morphology and mobility. Normal pulmonic and aortic outflow velocities with laminar flow. No obvious aortic or pulmonic insufficiency. No pericardial or pleural effusion noted. No obvious cardiac masses.

## CARDIAC CHART

### AGE

10 years

### WEIGHT

26.3lbs

### INTERPRETED BY

Maggie Machen Lamy,  
DVM, DACVIM  
(Cardiology)

### IMAGING PERFORMED BY

G. Ferrer, DVM

### HOSPITAL NAME

Paseos Veterinary  
Center

### REFERRING VET

Dr. Cruz

### INVOICE

30688

### DATE

5/9/23

CANINE CARDIAC PARAMETERS	MR VMAX (m/s)	TR VMAX (m/s)	LA/AO (Boon method)	LA/AO (Heart Base; Swe)	FS (%)	EF (%)	EPSS (cm)
NORMAL PARAMETER	4.5-5.5	<2.7	1.3	<1.6	28-40	40-100	<0.6
PATIENT	5.8	2.0	NM	1.7	50	82	0.37
CANINE CARDIAC PARAMETERS	HR (BPM)	AV VMAX (m/s)	PV MAX (m/s)	BODY WEIGHT (kg)	LA 2D short axis Base view (cm)	LVIDd Avg; 2D and m-mode short axis (cm)	LVIDs Avg; 2D and m-mode short axis (cm)
NORMAL PARAMETER	50-100	0.7-1.7	0.7-1.6	BELOW	BELOW	BELOW	BELOW
PATIENT	92	0.7	0.8	11.9	2.3	4.2	1.8
*Normal chamber parameters expressed as a mean value (SD)				3	1.27 (5.3)	2.46 (2.46)	1.36 (5.5)
<b>BODY WEIGHT DEPENDENT PARAMETERS</b>				5	1.40 (4.5)	2.74 (5.2)	1.60 (4.7)
<i>*Note: All measurements based upon multi-modal images and methods. An average value is reported.</i>				10	1.50 (3.8)	3.27 (3.5)	2.06 (3.1)
				15	1.83 (2.0)	3.71 (2.4)	2.43 (2.1)
				20	2.02 (1.9)	4.14 (2.2)	2.80 (2.0)
				25	2.18 (2.4)	4.48 (2.9)	3.10 (2.5)
				30	2.33 (3.3)	4.83 (3.9)	3.39 (3.4)
				35	2.48 (4.3)	5.17 (5.0)	3.69 (4.5)
				40	2.62 (5.2)	5.48 (6.1)	3.96 (5.4)
				50	2.88 (7.1)	6.07 (8.3)	4.46 (7.4)

Adapted from June Boon, Veterinary Echocardiography, 1998  
Rishniw M and Hollis NE, J Vet Intern Med 2000; 14:429-435  
Hansson et al, Vet Rad and Ultrasound 2002  
Bonagura et al. Echocardiography: principles of interpretation, Vet Clin North Am 15:1177, 1995

## INTERPRETATION OF THE FINDINGS & FURTHER RECOMMENDATIONS

Chronic degenerative valve disease persists with evidence of progression. Previously mild MR has advanced to moderate, with increasing left heart dimensions. A small tricuspid leak has developed; however, pulmonary pressures appear normal. Moderate left atrial enlargement indicates there is relatively low risk for imminent complication, however risk for progression to spontaneous congestive heart failure in the future is elevated.

Based upon these findings, recommend institution of Pimobendan as below. Additionally, a baseline BP is recommended. Continued assessment of progression is recommended, with a



**PATIENT**

Rodrigo Davila  
Gonzalez

guarded prognosis going forward (stage B2). Patient may be at risk for development of CHF, arrhythmias, and/or sudden death going forward.

**SPECIES**

Canine

Omega fatty acid supplementation and mild salt restriction may also be of some long-term benefit. Monitor for development of a progressive cough, labored breathing, exercise intolerance or collapse episodes.

**BREED**

Miniature Schnauzer

Once on the medication for 3-5 days, anesthetic risk remains mildly elevated. Cardiac protective drug choices (opioid/benzodiazepine premedication, Propofol or alfaxalone induction, iso or sevo gas) are recommended. Monitor for arrhythmias, hypotension, and hypoxia both intra and post-operatively and intervene as necessary. Judicious IV fluid rates are recommended to avoid fluid overload. Avoid heart rate stimulating drugs such as atropine unless clinically indicated.

**SEX**

Male Neutered

**PLAN**

Baseline BP recommended every 6 months. Institute Pimobendan 0.25-0.3mg/kg PO q12h.

**AGE**

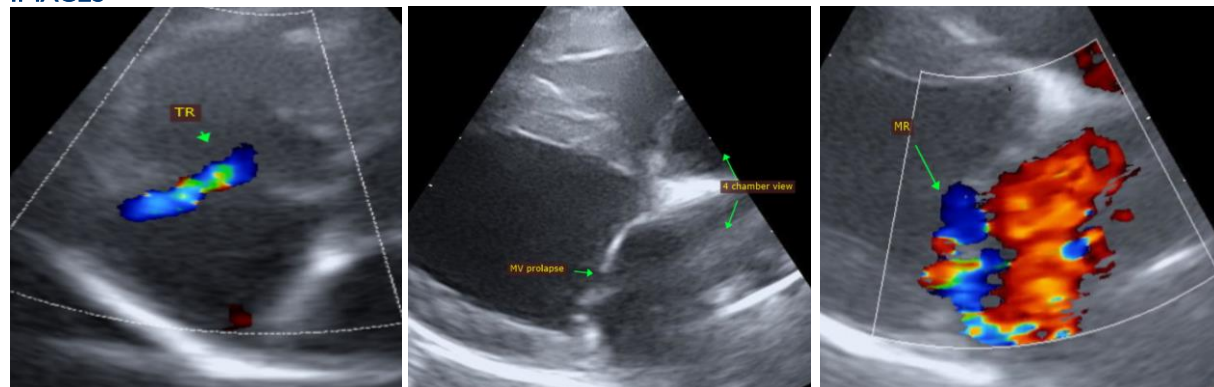
10 years

Recommend monitor for progression with a recheck echocardiogram in 6 months, sooner if any development of clinical signs.

**WEIGHT**

26.3lbs

**IMAGES**



**INTERPRETED BY**

Maggie Machen Lamy,  
DVM, DACVIM  
(Cardiology)

The information and recommendations provided are based on the images presented by the referring veterinarian. No evaluation can be communicated regarding pathology that was not visible in the image/video clips provided.

**IMAGING PERFORMED BY**

G. Ferrer, DVM

**HOSPITAL NAME**

Paseos Veterinary  
Center

Thank you for this referral. This report was generated using transcription software, and minor dictation errors may be present. If the clinical or image interpretation does not parallel your findings or if I can be of any further assistance, please contact me.

**REFERRING VET**

Dr. Cruz

**Maggie Machen Lamy, DVM**  
Diplomate of the American College of Veterinary Internal Medicine (Cardiology)  
info@sonopath.com

**INVOICE**

30688

**DATE**

5/9/23